PubMed Central
Search Journal List

NIH Public Access
Author Manuscript
Accepted for publication in a peer reviewed journal
About Author manuscripts | Submit a manuscript

Journal List > NIHPA Author Manuscripts

Abstract
Full Text
PDF (6.7M)

Related material:
PubMed related arts
GO
PubMed articles by:
Taubenberger, J.
Morens, D.

Top
Abstract
INTRODUCTION
CONCLUSION
LITERATURE CITED

Top
Abstract
INTRODUCTION
CONCLUSION
LITERATURE CITED

NIH-PA Author Manuscript
NIH-PA Author Manuscript
NIH-PA Author Manuscript

Annu Rev Pathol. Author manuscript; available in PMC 2008 August 11.
Published in final edited form as:
Annu Rev Pathol. 2008; 3: 499–522.
doi: 10.1146/annurev.pathmechdis.3.121806.154316.

PMCID: PMC2504709
NIHMSID: NIHMS54784

Copyright notice and Disclaimer

The Pathology of Influenza Virus Infections

Jeffery K. Taubenberger and David M. Morens

National Institute of Allergy and Infectious Diseases, National Institutes of Health, Bethesda, Maryland 20892
email: taubenbergerj/at/niaid.nih.gov, Email: dmorens/at/niaid.nih.gov

The publisher's final edited version of this article is available at Annu Rev Pathol.
See other articles in PMC that cite the published article.

Abstract

Influenza viruses are significant human respiratory pathogens that cause both seasonal, endemic infections and periodic, unpredictable pandemics. The worst pandemic on record, in 1918, killed approximately 50 million people worldwide. Human infections caused by H5N1 highly pathogenic avian influenza viruses have raised concern about the emergence of another pandemic. The histopathology of fatal influenza virus pneumonias as documented over the past 120 years is reviewed here. Strikingly, the spectrum of pathologic changes described in the 1918 influenza pandemic is not significantly different from the histopathology observed in other less lethal pandemics or even in deaths occurring during seasonal influenza outbreaks.

Keywords: pandemic, pneumonia, bronchitis, alveolitis, 1918 influenza, H5N1

"We regret very much the fact that an influenza virologist is unable to live say 200 years, so that he himself would be able to see what has developed from his earlier assumptions."

J. Mulder and J.F.P. Hers: Influenza (1)

NIH-PA Author Manuscript

Influenza virus

an antigenically and genetically diverse group of viruses of the family *Orthomyxoviridae* that contains a negative-sense, single-stranded, segmented RNA genome

Pandemic

a global outbreak caused by a new strain of influenza A virus that contains an antigenically novel hemagglutinin protein; efficiently transmitted from person to person

Pneumonia

an inflammation of the lungs (the lower respiratory tree) caused by a wide variety of microorganisms, including bacteria and viruses

Seasonal (interpandemic or epidemic) influenza

an outbreak of influenza A or influenza B virus occurring in annual cycles, usually in the winter months in temperate climates

Highly pathogenic avian influenza (HPAI)

a variant of avian influenza virus in which mutations in the cleavage site of hemagglutinin produce a virus that causes lethal infections in poultry

Top

Abstract

INTRODUCTION

CONCLUSION

LITERATURE CITED

INTRODUCTION

Influenza viruses are among the most common causes of human respiratory infections (2), and among the most significant because they cause high morbidity and mortality. Influenza outbreaks have apparently occurred since at least the Middle Ages, if not since ancient times (3). In the elderly, in infants, and in people with chronic diseases, influenza is associated with especially high mortality. In the United States, influenza results in approximately 200,000 hospitalizations and 36,000 deaths in a typical endemic season (4).

In addition to annual winter outbreaks, pandemic influenza viruses occasionally emerge (5, 6), as they have every 8 to 41 years for at least several centuries. Up to 50% of the population can be infected in a single pandemic year, and the number of deaths caused by influenza can dramatically exceed what is normally expected (7, 8).

Author Manuscript NIH-PA Author Manuscript NIH-PA Author Manuscript NIH-PA Author Manuscript

Since 1700, there have been approximately a dozen influenza A virus pandemics; in the past 120 years there were pandemics in 1889, 1918, 1957, and 1968 (9). The 1957 pandemic caused 66,000 excess deaths in the United States (8). In 1918, the worst pandemic in recorded history caused approximately 546,000 excess deaths (675,000 total deaths) in the United States (6) and killed up to 50 million people worldwide (10). It is very likely that influenza will return in pandemic form (5, 6, 9). Influenza B viruses can periodically cause large epidemics but do not cause pandemics. Influenza C viruses are endemic and sporadically cause mild respiratory disease. This review concentrates primarily on the pathology of influenza A viruses, by far the most important human influenza pathogens.

The spectrum of influenza A histopathology is variable. Because pathology studies have emphasized autopsy material, only changes associated with lethal outcomes and predominantly late-stage disease have been well characterized. There is a broad spectrum of changes associated with influenza infection, varying with both clinical picture and length of the disease course before death. Coincident or secondary bacterial pneumonias are not only extremely common in severe influenza but also complicate the histopathologic appearance. Nevertheless, the spectrum of observed pathologic changes appears to vary little from pandemic to pandemic or in interpandemic years (1, 11–22). What separates the 1918 influenza cases from cases seen in less severe pandemics and in seasonal influenza infections is not the spectrum of observed pathology in severe and fatal cases but the significantly higher case fatality rate and—in the 1918 pandemic only—an unusual age distribution of deaths. In 1918, many previously healthy young adults succumbed to fatal influenza infection, whereas the elderly had lower than expected fatality rates. In the past two pandemics and especially in interpandemic seasonal influenza cases, fatal cases tended to occur in people with underlying chronic illnesses or at the extremes of age (4, 8).

Concern about the emergence of an influenza pandemic caused by a highly pathogenic avian influenza (HPAI) virus of H5N1 subtype (23–26) makes reviewing the pathology of previous pandemics relevant. Unfortunately, only three autopsy examinations have been reported for individuals dying after H5N1 infection (27, 28). Whether the typical spectrum of influenza pathology would be observed if additional pathology studies were performed remains unclear. It has been proposed that the pathogenesis of H5N1 influenza virus infection may feature a unique hypercytokinemia (29, 30). Data also suggest that the H5N1 virus may replicate outside the respiratory tree (28). It is crucial for pandemic preparedness planning that additional careful and complete autopsy studies of H5N1 influenza viral infection be performed and reported to answer important questions about natural history, pathology, and pathogenesis.

Clinical Course of Disease

NIH-PA Author Manuscript

Influenza is an acute respiratory disease characterized in its full form by the sudden onset of high fever, coryza, cough, headache, prostration, malaise, and inflammation of the upper respiratory tree and trachea. In most cases, pneumonic involvement is not clinically prominent. Acute symptoms and fever often persist for 7 to 10 days. Weakness and fatigue may linger for weeks. Influenza usually occurs in winter outbreaks or epidemics (in temperate climates). People of all ages are afflicted, but the prevalence is greatest in school-age children; disease severity is greatest in infants, the aged, and those with underlying illnesses. Croup (laryngotracheitis) can be a serious complication in small children. Influenza A and B viruses are the most common causes of influenza-like illness (ILI), but other pathogens also cause ILI, including influenza C viruses, parainfluenza viruses, respiratory syncytial viruses, and *Mycoplasma pneumoniae* . At the peak of an influenza epidemic, approximately one-third of isolates from patients with ILI will be positive for influenza A (31).

People with chronic pulmonary or cardiac disease, or diabetes mellitus, are at high risk of developing severe complications from influenza A viruses, which may include hemorrhagic bronchitis, pneumonia (primary viral or secondary bacterial), and death. Hemorrhagic bronchitis and pneumonia can develop within hours. Fulminant fatal influenza viral pneumonia occasionally occurs; dyspnea, cyanosis, hemoptysis, pulmonary edema, and death may proceed in as little as 48 hours after the onset of symptoms.

Influenza A viral replication peaks approximately 48 hours after inoculation into the nasopharynx and declines slowly, with little virus shed after about six days. The virus replicates in both the upper and lower respiratory tract. Even after the infectious virus can no longer be recovered, viral antigen can be detected in cells and secretions of infected individuals for several days (2). The diagnosis of influenza can be established by viral culture, demonstration of viral antigens, or demonstration of viral genetic material (in clinical specimens), or rises/falls in specific antibody titers in serum or respiratory secretions (32).

ILI

influenza-like illness

Bronchitis/bronchiolitis

an inflammation of the bronchi and bronchioli of the respiratory tree

NA

neuraminidase

NIH-PA Author Manuscript NIH-PA Author Manuscript NIH-PA Author Manuscript NIH-PA Author Manuscript

Effective measures against influenza A and B diseases include prevention of infection by either vaccination with inactivated or live attenuated vaccines, or administration of antiviral drugs prophylactically or therapeutically (33). Studies of healthy young adults have shown influenza vaccine to be 70% to 90% effective in preventing influenza A illness, with moderately lower efficacy rates in the elderly. However, vaccines normally protect only for a matter of months; in any case, continuous viral antigenic drift (gradually accumulating mutations that allow escape from population immunity) of influenza A viruses makes once effective vaccines ineffective after a few years' time (34). Annual revaccination is thus recommended for those at high risk. The importance of predicting the emergence of new circulating influenza strains for subsequent annual vaccine development cannot be underestimated (35). Such surveillance is the cornerstone of the World Health Organization influenza surveillance network (36).

Antiviral drugs can have both therapeutic and prophylactic effects, but to prevent disease they must be administered continuously at times of high influenza activity. Matrix 2 ion channel blockers (amantadine and rimantadine) are effective against influenza A viruses, but resistant viral strains develop rapidly and have been recognized in approximately one-third of treated patients. The more recently developed neuraminidase (NA) inhibitors, zanamivir and oseltamivir, are effective against both influenza A and B viruses. Both classes of drugs are effective in preventing influenza when administered prophylactically (37–42).

Biology of Influenza Viruses

Influenza viruses (of the family *Orthomyx-oviridae*) are enveloped negative-strand RNA viruses with segmented genomes containing seven to eight gene segments (43). One genus includes influenza A and B viruses, and the other comprises influenza C viruses. The three virus types differ in host range and pathogenicity. Type B and C influenza viruses are isolated almost exclusively from humans, although influenza B viruses have been isolated from seals and influenza C viruses have been isolated from pigs and dogs (44, 45). Influenza A viruses, however, infect a wide variety of warm-blooded animals, including birds, swine, horses, humans, and other mammals. Avian influenza viruses in aquatic birds serve as the natural reservoir for all known subtypes of influenza A virus and probably are the ultimate source of human pandemic influenza strains (46). Influenza A viruses are subdivided by antigenic characterization of the hemagglutinin (HA) and NA surface glycoproteins that project from the virion. Sixteen HA and 9 NA subtypes are known (47).

NIH-PA Author Manuscript

Avian influenza

a genetically and antigenically diverse group of influenza A viruses replicating in the gastrointestinal or respiratory tracts of wild birds and domestic poultry, usually causing no or only mild symptoms

HA

hemagglutinin

World Health Organization guidelines for the nomenclature of influenza viruses are as follows. First, the type of virus is designated (A, B, or C), then the host (if non-human), place of isolation, isolation number, and year of isolation (separated by slashes). For influenza A, HA (H1–H16) and NA (N1–9) subtypes are noted in parentheses. For example, strains included in the most recent trivalent vaccine for the 2006–2007 season in the United States were: A/New Caledonia/20/1999 (H1N1)- like, A/Wisconsin/67/2005 (H3N2)-like, and B/Malaysia/2506/2004-like (48). The 1918 pandemic virus was an H1N1 strain. Its descendants circulated in humans until 1957 when they were replaced by an H2N2 subtype pandemic strain. H2N2 viruses circulated until 1968 when replaced by H3N2viruses of the 1968 pandemic. In 1977, H1N1 strains from the pre-1957 period reappeared, and since then both influenza A subtypes H3N2 and H1N1 have co-circulated in humans (46).

Influenza A and B viruses have a similar structure, whereas influenza C is more divergent. A and B type viruses contain eight discrete gene segments, each of them coding for at least one protein. They are covered with projections of three proteins: HA, NA, and matrix 2 (M2). Influenza C viruses have seven segments and only one surface glycoprotein (43). Each influenza RNA segment is encapsidated by nucleoproteins to form ribonucleotide-nucleoprotein complexes (43).

Influenza viruses accumulate point mutations during replication because their RNA polymerase complex has no proofreading activity (43). Their genes have high mutation rates (ranging from approximately 1×10^{-3} to 8×10^{-3} substitutions per site per year) (49). Mutations that change amino acids in the antigenic portions of surface glycoproteins may produce selective advantages for viral strains by allowing them to evade preexisting immunity. The HA molecule initiates infection by binding to receptors on specific host cells. Antibodies against the HA protein prevent receptor binding and are effective at preventing re-infection with the same strain. The HA and NA can evade previously acquired immunity by either (*a*) antigenic drift, in which mutations limit or prevent antibody binding, or (*b*) antigenic shift, in which the virus acquires HA of a new subtype by reassortment between two influenza A viruses (2). Sixteen HA subtypes are known to exist in wild birds and provide a source of HAs novel to humans (46, 47). The emergence in human circulation of an influenza strain with a novel subtype by antigenic shift has been the cause of the past two influenza pandemics (in 1957 and 1968); in both

NIH-PA Author Manuscript

cases, the previously circulating postpandemic human virus imported an HA from an unidentified avian or avian-like virus (50). Although one of the absolute requirements for a pandemic is that HA must change, the extent to which the rest of the virus can or must change is not known. In 1957, three genes from the circulating H1N1 human influenza virus were replaced by avian-like genes: HA, NA, and a subunit of the polymerase complex (PB1). In 1968, the HA and PB1 genes were similarly replaced (50, 51). The 1918 virus was recently completely sequenced using archevirologic techniques in which reverse-transcriptase polymerase chain reaction (RT-PCR) for small fragments of viral RNA were analyzed from lung tissues of 1918 influenza victims (52–57). The 1918 influenza pandemic virus has an avian-like genome and, unlike the 1957 and 1968 viruses, is hypothesized to have arisen instead by whole genome adaptation (6, 57–59).

Although an antigenically novel HA subtype is a likely requirement for the emergence of an influenza pandemic, human infections with animal-adapted influenza virus of novel HA subtype have been observed in which the virus is not transmitted efficiently from person to person, suggesting that stable adaptation to humans by reassortment or whole genome adaptation is required for the emergence of a pandemic strain (26). For example, in the 1976 exposure of a limited number of soldiers to a swine-adapted H1N1 influenza virus in Fort Dix, New Jersey, there was one death (60, 61). In 2003, an HPAI H7N7 virus caused a poultry epizootic in the Netherlands and spread regionally. Before the epizootic was contained, at least 86 poultry workers and three contacts had been infected and developed conjunctivitis with or without an ILI. There was one fatality among those with direct contact to poultry (62). Similarly, two people developed influenza conjunctivitis during a 2004 H7N3 HPAI outbreak in Canada (63).

After reemergence in 2003, the ongoing H5N1 HPAI epizootic continued to produce spillover infections in humans, causing concern that adaptation of this virus to humans could cause a pandemic (26). As of April 2007, 291 confirmed cases of human H5N1 infection had been documented, of which 172 were fatal (64), yielding a case fatality rate of 59%. Concerns about the emergence of an H5N1 pandemic virus hinges not only upon transmission events between infected poultry and individual humans, but also upon the development of sustained human-to-human transmission. Several case clusters of H5N1 infections have been reported (65). Although epidemiologic information has been limited, person-to-person transmission of H5N1 has been suggested in a few instances, usually involving family members. It is unknown whether this represents infection associated with particularly intimate or prolonged contact, or shared but unidentified host factors affecting either infection risk or virus transmissibility.

RT-PCR

reverse-transcriptase polymerase chain reaction

NIH-PA Author Manuscript NIH-PA Author Manuscript NIH-PA Author Manuscript

The 1918 pandemic was the most lethal influenza pandemic on record. Most communities experienced morbidity of 25%–40%, and the vast majority of cases were self-limited. Age-specific morbidity was similar to other pandemics, with children under 15 years of age experiencing the highest rates of infection (66). Clinically, the 1918 pandemic presented generally the same symptoms and course as influenza of other years, and, pathologically, the disease was similar to other pandemics in that severe complications were confined largely to the respiratory tract (20, 21).

However, the 1918 pandemic differed from other pandemics in several important clinical and epidemiologic aspects. Although the clinical course was usually self-limiting, a substantially higher percentage of cases developed severe pneumonic complications. As a result, the case mortality rate in the United States averaged 2.5%, several times higher than the current rate. Moreover, mortality during the 1918 pandemic was concentrated in an unusually young age group (6). People under the age of 65 accounted for more than 99% of excess influenza-related deaths in 1918. In contrast, in the 1957 and 1968 pandemics, people less than 65 years old accounted for only 36% and 48% of excess deaths due to influenza, respectively (67). The age group affected most severely by the 1918 pandemic was that between 20 and 40 years, and this group accounted for almost half of influenza deaths during the pandemic. The reasons for these unexpected patterns remain obscure.

INFLUENZA PATHOLOGY

Influenza virus replicates in the epithelial cells throughout the respiratory tree, with virus being recoverable from both the upper and lower respiratory tract of people naturally or experimentally infected (2). As histologic changes are nonspecific, histologic analysis alone is insufficient to make a specific diagnosis (19); diagnosis typically requires supporting diagnostic tests such as viral isolation, rapid diagnostic tests (including RT-PCR), serologic studies, or a biopsy or autopsy tissue section confirmed by in situ hybridization or immunohistochemical techniques (32). Non-fatal influenza viral infections predominantly involve the upper respiratory tract and trachea, but fatal cases of influenza usually show evidence of pneumonia. This review concentrates on the pathology of the lower respiratory tract.

Tracheobronchial Changes in Influenza

Starting with the first pathological studies of influenza associated with the 1889 pandemic (15, 68, 69), involvement of epithelial cells lining the upper respiratory tract has been universally recognized and corresponds to the clinical signs and symptoms of pharyngitis and tracheobronchitis. The large number of autopsy studies reported during and after the 1918 influenza pandemic all report such changes, particularly severe tracheitis. Winternitz and his coworkers, however, clearly recognized that the epithelium of the trachea, bronchi, and the pulmonary alveoli were primary sites of influenza viral

NIH-PA Author Manuscript

replication. They were among the only observers of the 1918 pandemic to reach such a conclusion (20). At autopsy, the almost constant coexistence of secondary bacterial infections of the air passages in fatal interpandemic and pandemic influenza complicates the picture, making it difficult to ascribe observed changes solely to influenza virus infection.

In the acute stage, multifocal destruction and desquamation of the pseudostratified pseudostratified columnar epithelium of the trachea and bronchi are characteristic. Often only a basal layer of the epithelium remains. Edema and congestion of the submucosa are often marked (20). These changes were carefully described by several distinguished pathologists in the aftermath of the 1918 influenza (20, 70–72). In later stages, Askanazy observed evidence of epithelial regeneration with the formation of a nonkeratinizing stratified squamous metaplasia in 38 of 90 cases (70).Winternitz et al. (20) reported similar findings.

Lucke et al. (73) reported a series of 126 autopsies performed in 1918. The trachea and bronchi had markedly reddened and swollen mucosal surfaces, sometimes overlaid with mucopurulent material. Hemorrhagic tracheitis and bronchitis were observed in 50% of cases. The lumina contained large amounts of frothy blood-stained material. In Mulder & Hers' (1) meticulous cytopathologic and histopathologic examinations of influenza cases, based predominantly on 1957 pandemic autopsy cases, these pathologic changes are described in great detail. Their findings reiterate pathologic changes observed in 1918 and are concordant with the smaller number of influenza pathology studies published in recent decades.

Ciliated pseudostratified epitheepithelium of trachea and bronchi

Early structural changes caused by influenza virus in the epithelium of the upper airway are variable, including cytonecrosis initially involving shrinkage and vacuolization, followed by desquamation of these cells into the luminal space. Necrotic cells may also undergo phagocytosis by macrophages. These structural changes to the epithelium are often irregularly distributed, and regions of pathology can abut areas appearing histologically normal. The final stage of desquamation of the affected epithelium frequently shows only a single layer of flattened basalar epithelial cells covering the basement membrane. Complete separation of the remaining epithelium may be a histologic artifact. An outstanding feature in early stages of infection is the absence of neutrophils in the infiltrate, but as epithelial cell necrosis occurs, these cells migrate in. Later stages show mononuclear inflammatory cell infiltrates in the walls of bronchi (20).

Ducts of the mucus glands

Opie (20) and Winternitz et al. (74) both initially described the degeneration of epithelial cells in the

Manuscript NIH-PA Author Manuscript NIH-PA Author Manuscript NIH-PA Author Manuscript

tracheal and bronchial mucus glands in influenza infection. As in the overlying epithelium, changes consist of cytonecrosis and desquamation. Mulder & Hers (1) made similar observations about the 1957 pandemic.

Epithelium of the bronchioli

Changes in the smaller airways are similar to those described above for larger airways. Goodpasture (75) described the pathology of small- and medium-sized bronchioles in 1919. Grossly, in early cases, the epithelial linings are erythematous and filled with thin blood-stained froth or fluid. In later cases, the epithelia are necrotic. Because of the simpler structure of the bronchiolar epithelium, thinning and flattening of these cells can be more pronounced than in the larger airways. Complete loss of the epithelial layer can be seen (both ciliated and goblet cells), often associated with the formation of hyaline membranes at these sites. A neutrophilic exudate may be present in the bronchiolar lumen. The interstitium may show congestion, edema, and an inflammatory infiltrate. Air spaces may be filled with edema, fibrin, and varying numbers of neutrophils (19). Lucke et al. (73) reported desquamative bronchiolitis, often accompanied by ulceration. They noted submucosal capillary congestion and thrombi and found that the bronchiolar wall was sometimes entirely necrotic and associated with a polymorphonuclear cell infiltrate. Photomicrographs of necrotizing bronchiolitis from two 1918 pandemic autopsy cases are shown in Figures 1 and 2. Opie et al. (71) described the profound changes in smaller bronchi and felt that they were a characteristic feature of influenza virus infection. Common changes include focal epithelial necrosis to necrosis of the entire wall, peribronchial hemorrhage, and peribronchial pneumonia.

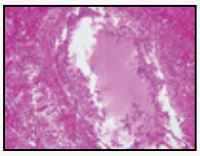

Figure 1

H&E-stained section of the lung from a 1918 influenza victim showing necrotizing bronchiolitis. There is necrosis of the bronchiolar wall, with submucosal edema and vascular congestion. The epithelial layer is desquamating, and necrotic epithelial (more ...)

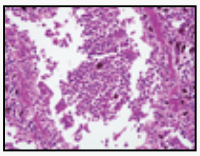

Figure 2

H&E-stained section of the lung from a 1918 influenza victim showing necrotizing bronchiolitis. There is necrosis of the bronchiolar wall. The epithelial layer is desquamating, and necrotic epithelial cells are present in the lumen. A mixed inflammatory (more ...)

Other histologic changes

NIH-PA Author Manuscript

Influenza infection of the epithelium of the upper airway passages is also associated with vascular congestion and hyperemia, edema, and an inflammatory cell infiltration of the tunica propria and submucosa. Infiltration of neutrophils penetrating from capillaries into virus-infected areas in the absence of any evidence of secondary bacterial infection may be observed; however, neutrophilic infiltration is never massive. The presence of many neutrophils within the epithelial layer strongly suggests a coincident or secondary bacterial infection. A mononuclear-cell-inflammatory infiltrate of lymphocytes, histiocytes, and plasma cells is frequently found in the tunica propria and submucosa of influenza-infected airways.

In situ hybridization or immunohisto-chemical analysis for influenza virus in sections of the upper airway

Studies performed in the 1950s and 1960s (1), and more recent studies (12, 13), have consistently demonstrated the presence of influenza virus in tracheobronchial epithelial cells. Like the variable and multifocal histopathology, staining is usually focal. Both necrotic and histologically-normal-appearing cells can be positively stained. Mononuclear inflammatory cells may also stain positively.

Evidence of epithelial repair and regeneration

Mitotic activity in regenerating respiratory epithelium can be seen focally. In 14 cases of interpandemic influenza (1947–1954) Mulder & Hers found regeneration in 3 cases, all with courses of 5–14 days after onset of illness. In 11 cases in which death occurred in less than 5 days, they found variable mitotic activity but no evidence of true regeneration of the epithelial layer. In pandemic material, they found 13 cases out of 241 with regenerating epithelium (1). From these studies, and those of the 1918 pandemic (20), it appears likely that in influenza infection epithelial regeneration starts after approximately 5 days. Chronic effects include squamous metaplasia and interstitial fibrosis (19).

Influenza Virus Pneumonia

Classic histopathologic studies of influenza autopsies have clarified the changes characteristic of severe influenza viral pneumonia, namely, capillary and small vessel thromboses, interstitial edema and inflammatory infiltrates, the formation of hyaline membranes in alveoli and alveolar ducts, varying degrees of acute intraalveolar edema and/or hemorrhage, and diffuse alveolar damage in addition to necrotizing bronchitis and bronchiolitis. Later stages show organizing diffuse alveolar damage, fibrosis, epithelial regeneration, and squamous metaplasia. Secondary or coincident bacterial pneumonias frequently occur and complicate the pathologic picture. In such cases, a massive infiltration of neutrophils into alveolar air spaces is observed, and alveolar hemorrhage and edema are less pronounced than in primary influenza virus pneumonia (73). An example of the massive neutrophil infiltration in acute bacterial bronchopneumonia is shown in Figure 3. Additional changes associated

NIH-PA Author Manuscript

with secondary bacterial pneumonias vary by causative agent and time course to death and are not further described in this review.

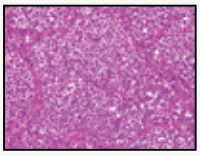

Figure 3

H&E-stained section of the lung from a 1918 influenza victim showing a massive infiltrate of neutrophils that fills the alveolar air spaces in early bacterial bronchopneumonia. Alveolar capillary congestion is prominent (original magnification (more ...)

Early pathologic descriptions of influenza pneumonia were made in the 1889 pandemic, depicting a gross pathologic picture of an edematous, hemorrhagic bronchopneumonia (15, 68, 69). This fits the clinical picture of influenza viral pneumonia, as described by Leichtenstern in 1896 (15), with patients showing marked dyspnea and developing cyanosis. Influenza viral pneumonia patients often produce massive amounts of foamy, blood-tinged, or frankly hemorrhagic sputum (15).

Large-scale autopsy studies by prominent pathologists during the 1918 influenza pandemic first described the spectrum of changes associated with influenza virus pneumonia. Never before or since have so many pathological studies of influenza pneumonia been described. During the 1918 pandemic, an edematous, hemorrhagic bronchopneumonia often occurring concurrently with focal bacterial pneumonia was reported by many physicians and pathologists, compatible with findings reported in the aftermath of the 1889 pandemic. Most notable among them are the classic 1918 pandemic studies by Goodpasture (75), Klotz (76), LeCount (14, 77), MacCallum (72), Opie et al. (71, 74), Walker (78), Winternitz et al. (20), Wolbach (21), and Wolbach & Frothingham (79).

Alveolitis

an inflammation of the alveoli, the air sacs of the lungs

Even though the first isolation of human influenza virus did not occur until 1933 (80), many pathologists had long suspected an underlying primary influenza viral pneumonia could be described separately from secondary bacterial pneumonias. Many pathologists in 1918 rejected the hypothesis that *Bacillus* (now *Haemophilus*) *influenzae* (Pfeiffer's bacillus) was the causative agent of influenza because in a number of series it was recovered in only a minority of cases at autopsy (81). Wolbach performed large autopsy studies in Boston and at nearby Camp Devens during the pandemic (21) and in 1923 wrote,

NIH-PA Author Manuscript

> **Pathologists who have reported on the pulmonary lesions have not always endeavored to separate the lesions due to the virus of the epidemic and those dependent on the complicating organisms. On account of the variety of complicating organisms, manifold gross pathologic appearances have been described, and a sharp separation between lesions produced by the virus of the epidemic disease and the complicating organisms has not been made (79).**

Goodpasture similarly wrote of his autopsy experiences in 1918:

> **One feels justified in formulating the opinion that influenza is a distinct disease, recognizable clinically only by its epidemiologic proportions and extreme infectiousness, characterized pathologically by peculiar lesions in the lungs, and caused by an unknown virus which gains entrance through the respiratory tract (75).**

Wolbach described the hyaline membranes and the diffuse alveolar damage (21). LeCount described the focal capillary and small vessel thromboses typical of influenza viral pneumonia (77). MacCallum (72) and Winternitz et al. (20) confirmed the above observations and described the underlying primary pulmonary lesion as most probably caused by an unknown nonbacterial (viral) agent. The histopathologic pattern that emerged from these studies matches the modern view of viral pneumonia, with changes of diffuse alveolar damage, prominent necrosis of the alveolar epithelium, the formation of hyaline membranes in dilated alveolar ducts and alveoli, capillary thrombosis with necrosis of the alveolar septa (necrotizing alveolitis), intraalveolar hemorrhage and edema, and cells with pyknotic nuclei in the alveolar air spaces (desquamated alveolar epithelial cells).

During and after the 1957 pandemic, a number of excellent autopsy studies of influenza viral infection were reported (17, 18, 82, 83). In 1972, Mulder & Hers published a comprehensive study of changes observed in these more recent fatal influenza pneumonias (1), which remains the definitive source on influenza pathology. One difference they noted was that acute alveolar edema was not as prominent a feature of influenza pneumonia as in 1918, although it was still observed. In a reexamination of autopsy material of fatal interpandemic seasonal influenza cases from 1922–1947, they reported that changes of primary influenza virus pneumonia were not frequently observed, although changes typical of influenza were seen in the air passages. However, most interpandemic influenza cases had longer courses and secondary bacterial pneumonias.

In the 1968 pandemic, other groups also reported on the pathologic changes observed in fatal influenza

uthor Manuscript NIH-PA Author Manuscript NIH-PA Author Manuscript NIH-PA Author Manuscript

pneumonia cases (11, 16, 84). Even though overall case mortality was low in the 1968 pandemic, as compared with the 1957 pandemic, the same spectrum of pathology was observed. In both the 1957 and 1968 pandemics, previously healthy individuals with no underlying chronic illnesses succumbed to fatal influenza viral pneumonias.

Histopathology of Primary Influenza Virus Pneumonia

The alveolar epithelial cell lining is as much a target of influenza infection as the epithelial covering of the bronchi and bronchioles. Three characteristic alveolar changes are seen in early influenza virus pneumonia: capillary thrombosis, focal necrosis of the alveolar wall, and development of hyaline membranes. Early lesions of the alveolar epithelium are often difficult to detect because of the hyperemic, partly hemorrhagic edematous pneumonia that develops with infection (1). Alveolar lining cells also undergo necrotic changes and desquamation. Immunofluorescence studies documented influenza virus replication in alveolar epithelial cells in 1957 pandemic cases (1).

Degenerative changes include cytoplasmic vacuolization and nuclear pyknosis. Vast numbers of desquamated cells may be observed in the luminal spaces of alveoli, alveolar ducts, and bronchioli together with macrophages showing phagocytosed cellular debris. At a certain stage in influenza virus pneumonia, alveolar cells partially or completely disappear (20, 72, 76). Late stages show the presence of regenerating alveolar epithelium (type II alveolar hyperplasia) (1, 19).

These cytologic changes were observed in alveolar lining cells in influenza virus pneumonia, as described by MacCallum, in 11 of 44 cases. In 8 of these 11 cases, he also observed hyaline membranes, whereas 4 of 11 cases showed thromboses in the capillaries of the alveolar septa. The cytologic changes are similar to those seen in ciliated cells of the upper air passages (72). Mulder & Hers (1) found these changes in 52 of 79 cases from the 1957 pandemic. In affected areas, alveolar macrophages are sometimes present in large numbers and may show mitotic activity. They can demonstrate phagocytosis of degenerate, desquamated alveolar lining cells, leukocytes, and sometimes erythrocytes. Some show degenerate changes and may also be infected primarily with influenza virus (supported by in situ hybridization studies).

Hyperemia of the alveolar wall caused by marked capillary congestion is invariably present in influenza virus pneumonia. The alveolar septa are considerably thickened by dilatation of the alveolar capillary bed. This dilatation is responsible for the diffuse red color of the affected areas (20). Fibrinous capillary thrombi, first described by LeCount in 1919, are found in both the walls of alveolar ducts and in the alveolar septa (77). Leukocyte infiltration of the hyperemic alveolar septa is always present in the early stages of influenza virus pneumonia. The leukocytes are predominantly neutrophils and occasionally eosinophils. Infiltration is never dense except in areas showing septal necrosis. When hyperemic alveolar septa show no leukocytic infiltration, the diagnosis of influenza pneumonia should be doubted.

NIH-PA Author Manuscript

Later stages of influenza virus pneumonia also show interstitial infiltrates of mononuclear leukocytes, predominantly lymphocytes and plasma cells. Megakaryocytes lying within the capillary bed are also commonly observed (1).

Necrosis of the alveolar wall may be a result of capillary thrombosis (77). The extent and number of necrotic sites vary. Necrotic areas are associated with leukocytic infiltrates, exudation of fibrin, and disappearance of alveolar lining cells. Endothelial cell necrosis with pyknotic nuclei may be observed. Hemorrhage into the alveolar air spaces is often observed near necrotic areas, associated with the exudation of plasma and strands of fibrin. Alveolar air spaces adjacent to areas of necrosis of the alveolar walls usually contain an accumulation of desquamated alveolar cells (1, 75). A photomicrograph of necrotizing alveolitis with intraalveolar edema, fibrin, inflammatory cells, and desquamated alveolar epithelial cells is shown in Figure 4. This 1918 autopsy lung tissue sample was positive by RT-PCR for influenza A virus A/New York/1/1918 (53).

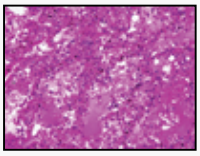

Figure 4

H&E-stained section of the lung from a 1918 influenza victim showing a pattern of necrotizing alveolitis. The alveolar walls are necrotic, and alveolar air spaces contain edema fluid, desquamated epithelial cells, and inflammatory cells (original (more ...)

NIH-PA Author Manuscript

Hyaline membranes first appear in respiratory bronchioles and alveolar ducts, then develop on the alveolar walls (21), as seen in a photomicrograph from another 1918 autopsy case (Figure 5). In later stages (usually after a clinical course of approximately one week), hyaline membranes may occur as coarse strands or fine strands merging into a network of fibrin in the alveolar air spaces. This picture of a meshwork of hyaline membranes within alveoli is a characteristic finding in fully developed influenza virus pneumonia. Hyaline membranes may also be observed covering small epithelial defects in bronchioli and small bronchi.

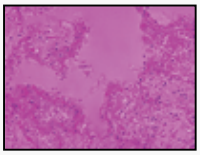

Figure 5

H&E-stained section of the lung from a 1918 influenza victim showing hyaline membranes lining an alveolar duct and adjacent alveoli. The alveolar air spaces contain edema fluid, strands of fibrin, desquamated epithelial cells, and inflammatory (more ...)

NIH-PA Author Manuscript

Intraalveolar edema and hemorrhage are outstanding features of influenza virus pneumonia. In general

NIH-PA Author Manuscript NIH-PA Author Manuscript NIH-PA Author Manuscript

their presence is associated with necrosis of the alveolar wall. A number of cases in 1918 demonstrated massive amounts of edema (see Figures 6 and 7) (20, 21), a finding less prominent in the 1957 pandemic material (see Figure 8) (1). Dilatation of the alveolar ducts is also a common feature in the acute stage of fatal influenza virus pneumonia described by many authors in 1918. Intraalveolar hemorrhage is often, but not always, associated with areas of necrosis of the alveolar wall. Hemorrhage can sometimes be extensive and may be grossly visible on a cut section as tiny or large hemorrhagic areas, and also beneath the pleura (74). Large hemorrhagic areas can sometimes be the result of secondary bacterial pneumonias. Wolbach & Frothingham (79) observed evidence of intraalveolar hemorrhage and edema and the formation of hyaline membranes in all of his cases. Good-pasture (75) found these features in all cases dying within a few days, and in 70% of cases with pneumonias accompanying influenza. All these cases occurred in healthy young soldiers or civilians. LeCount, summarizingfindings from 200 influenza autopsies in 1918, described a massive edematous exudate in lung tissue and bronchioles on cut section. He wrote that after the development of rigor mortis, this bloody edema fluid "pours out of the nostrils so as to stain a large part of the white sheets in which bodies are wrapped" (14).

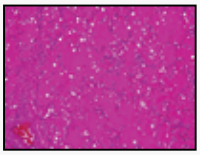

Figure 6

H&E-stained section of the lung from a 1918 influenza victim showing massive pulmonary edema. The alveolar air spaces contain edema fluid. A mild interstitial inflammatory cell infiltrate is also present (original magnification 40×).

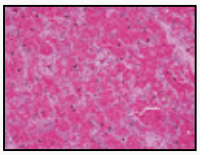

Figure 7

H&E-stained section of the lung from a 1918 influenza victim showing massive pulmonary hemorrhage. The alveolar air spaces contain erythrocytes. Interstitial edema and a mild interstitial inflammatory cell infiltrate are also present (original (more ...)

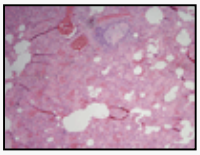

Figure 8

H&E-stained section of the lung from a 1957 influenza victim showing massive pulmonary edema and hemorrhage in early bronchopneumonia. The alveolar air spaces contain edema fluid and erythrocytes. A bronchiole shows necrotizing bronchiolitis with (more ...)

Unless successfully prevented by antibiotics, the late stages of influenza virus pneumonia are almost

NIH-PA Author Manuscript

always complicated by secondary bacterial pneumonia, which can also produce hemorrhage. In all of the Camp Devens autopsy cases described by Wolbach (79), bacteria were either cultured from lung tissue at autopsy or identified on sections. The earliest death in this series was seven days after on-set. The latest had a clinical course of 32 days.

Another histologic feature of the later stages of influenza virus pneumonia is evidence of repair and fibrosis. Regeneration of the epithelial lining of alveoli and bronchial tree with evident mitoses is frequently observed. Squamous metaplasia is common, and regenerating alveolar lining cells frequently show type II pneumocyte hyperplasia. Mulder & Hers (73) described 11 cases with a clinical course ranging from 8 to 21 days; in 4, epithelial regeneration was found in respiratory bronchioles and adjacent alveoli, including examples of mitotic figures. Interstitial fibrosis of alveolar walls is common as well. Also observed in late stages is erythrocyte phagocytosis by macrophages. In the variable spectrum of influenza virus pneumonia, different areas of the lung frequently demonstrate histologic lesions compatible with different stages of infection. Later stages may also show typical changes of organization and fibrosis, including interstitial fibrosis, and bronchiolitis obliterans (see Figure 9) with or without evidence of organizing pneumonia (19, 20, 74).

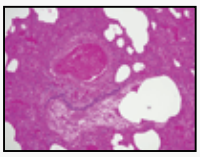

Figure 9

H&E-stained section of the lung from a 1918 influenza victim showing bronchiolitis obliterans. The surrounding alveoli show edema and hemorrhage. There is interstitial capillary congestion, and a peribronchiolar vessel shows a thrombus (original (more ...)

Influenza Virus Pneumonia in Interpandemic, Seasonal Influenza Cases

Note that the spectrum of pathologic changes seen in the 1918, 1957, and 1968 pandemic cases, including the features of fatal primary influenza virus pneumonia, has also been observed in fatal cases of interpandemic influenza. Noble et al. (85) reported such a case in 1973 in which an open lung biopsy revealed necrotizing bronchitis and bronchiolitis. Yeldandi & Colby (22) reported a histopathologic analysis of six cases with lung biopsies. Five patients recovered (two were treated with corticosteroids for bronchiolitis obliterans with organizing pneumonia), and one case was fatal. A biopsy showed variable features of influenza virus pneumonia that included patchy fibrinous alveolar exudates, alveoli with hyaline membranes, interstitial edema, late-stage severe diffuse alveolar damage, and bronchiolar necrosis. Reparative changes were also seen, defined as the proliferation of type II alveolar pneumocytes and mild interstitial chronic inflammatory infiltrates, as well as organization in air spaces and the interstitium (22).

NIH-PA Author Manuscript

Guarner et al. (13) reported eight fatal cases of influenza infection with both histopathology and antiviral detection by immunohistochemistry and in situ hybridization. Cases were divided into two groups on the basis of predominant histopathology: a tracheobronchitis group and an alveolitis group. The tracheobronchitis group sections showed focal positive immunohistochemical or in situ hybridization staining for influenza virus in intact and necrotic bronchial epithelial cells, as well as varying degrees of epithelial desquamation and necrotic debris in bronchial lumina. Three of these cases had necrotizing bronchitis. The second group had alveolitis with an abundant mononuclear inflammatory infiltrate. One case showed intraalveolar hemorrhage. In this group, no viral antigens or nucleic acids could be detected.

In another study, Guarner et al. (12) reviewed autopsy material on 47 pediatric deaths occurring during the 2003–2004 influenza season. As in the other studies, changes were seen in the trachea and bronchi, 90% of cases having submucosal congestion and 73% a mononuclear submucosal inflammatory infiltrate. Fifty percent of cases had necrosis of bronchial epithelium and submucosal hemorrhage. In the lower respiratory tree, 66% had a mononuclear interstitial inflammation and formation of hyaline membranes; 50% showed evidence of intraalveolar hemorrhage. Neutrophilic, bacterial bronchopneumonia was also observed in 50% of cases. Immunohistochemistry for influenza viral antigens was positive in 57% of cases. Positive staining was observed in bronchial epithelial cells; submucosal mucus glands of the trachea, bronchi, bronchioli; and in single cells in alveolar lumina (thought to represent sloughed bronchial epithelial cells, not alveolar lining cells). The best immunohistochemical staining was seen in those patients dying in less than three days. Hemophagocytosis was observed in 50% of cases; the authors speculated that it might have been associated with hypercytokinemia. Hemophagocytosis was also reported in both the 1918 and 1957 pandemics (1, 20).

The lack of detection of influenza virus antigens or nucleic acids in alveolar epithelial cells is interesting, especially in cases showing alveolar epithelial cell desquamation and diffuse alveolar damage, but this may be related to the time course of these cases. Mulder & Hers (1) reported positive in situ hybridization results for influenza RNA in the 1957 pandemic cases, but reported that primary influenza virus pneumonia was not a commonly observed feature of interpandemic influenza autopsy cases from 1942–1947.

Histopathologic Changes in H5N1 Highly Pathogenic Avian Influenza Infections

Since 2003, 328 documented cases of human H5N1 influenza viral infection have been reported (64), with 200 fatalities. To et al. (27) described the autopsy findings of two of the six individuals who died in the initial H5N1 human outbreak in Hong Kong in 1997. Both had clinical courses of greater than one month, with deaths attributed to multi-organ failure. The findings in the respiratory tree consisted of

NIH-PA Author Manuscript

extensive hemorrhage, organizing diffuse alveolar damage with interstitial fibrosis, and cystically dilated air spaces. One case showed an interstitial lymphoplasmacytic infiltrate and scattered histiocytes with reactive hemophagocytic activity. All these features are compatible with late-stage cases described by Winternitz et al. in their review of 1918 pandemic autopsies (20). Neither case showed evidence of a secondary bacterial pneumonia. Both, however, showed a reactive hemophagocytic syndrome in hematopoietic organs, which the authors postulated may have been triggered by reactive hypercytokinemia.

Uiprasertkul et al. (28) reported a single autopsy study from a fatal case in a six-year-old boy who developed acute respiratory distress and died after 17 days. In this case, the respiratory tree showed a proliferative phase of diffuse alveolar damage, interstitial pneumonia, focal hemorrhage, and bronchiolitis. Alveolar pneumocytes with reactive hyperplasia were seen without evident cytopathic changes. A secondary infection with a fungus, morphologically resembling an aspergillus species, was noted. No hemophagocytosis was observed. Immunohistochemical analysis for H5N1 detected positive staining in alveolar epithelial cells. Double staining with antibodies against surfactant demonstrated that these were type II pneumocytes. Interestingly, immunohistochemistry stains were negative in the tracheal epithelium. RT-PCR for replicative H5N1 RNA was positive not only in the lung tissue, but also in the large intestines.RTP-CR was negative in plasma and other organs.

A recent clinical study of human H5N1 infections demonstrated higher cytokine and chemokine levels in peripheral blood than in control patients with seasonal, endemic human influenza infection (29), and was highest in fatal H5N1 infections. The H5N1 cases were also characterized by high pharyngeal virus titers, and H5N1 virus was detected in one case in the rectum, suggesting the possibility of limited replication outside the respiratory respiratory tract. Respiratory tract cytokine and chemokine levels were not measured in this study, and no comparison is possible between these blood cytokine results and what would have been observed in past pandemic virus infections such as those of 1918 and 1957.

Experimental Animal Models of Influenza Virus Infection

Shope isolated the first influenza A virus from pigs in 1930 (86, 87), and after the subsequent isolation of human influenza A viruses in 1933 (80), ferrets were identified as an excellent laboratory model for human influenza. In a series of landmark papers, Shope reported on the histopathologic changes in the respiratory tract of pigs, ferrets, and mice, describing changes compatible with those in human influenza virus infection, namely, desquamation of the ciliated epithelium of the tracheobronchial airways and peribronchial mononuclear cell inflammatory infiltrates (86, 88, 89). The lungs of infected pigs and ferrets showed hyperemia and capillary congestion and mononuclear and neutrophilic inflammatory cell infiltrates in alveolar septa (often marked), necrosis and desquamation of alveolar epithelial cells, and interstitial and intraalveolar edema. Mice were susceptible to infection with human

NIH-PA Author Manuscript

and swine influenza viruses (90), but could not transmit the infection to other mice (89). In contrast, Shope showed that both ferrets and swine were able to transmit the virus to contact animals (86, 88). In 1962, Hers et al. (91) demonstrated, by in situ hybridization, viral replication in alveolar cells in experimental influenza infection in ferrets and mice. Although these experimental animal models and humans infected with influenza A viruses share many histologic features—including evidence of viral degeneration of alveolar lining, hyperemia and congestion, septal inflammatory infiltrates, the appearance of macrophages with necrotic cellular debris in air spaces, and intraalveolar edema and hemorrhage—human cases additionally demonstrate the formation of hyaline membranes and capillary thrombosis.

The use of nonhuman primates for human influenza virus infection has also been recently reevaluated. Burnet (92) reported experimental influenza virus infection of cynomolgus monkeys (*Macaca fascicularis*) in 1941 with a variant of A/WS/33 (H1N1). He reported histopathologic findings of bronchopneumonia, with necrotizing bronchiolitis, intraalveolar edema and fibrin, and a mixed inflammatory infiltrate. Murphy and colleagues published a series of studies on experimental influenza virus infection in various nonhuman primates in the 1980s (93–97). Recently, Baskin et al. (98) reported the pathology of a pigtail macaque (*M. nemestrina*) infected with a contemporary human H1N1 influenza virus, and Baas et al. (99) analyzed host gene expression profiles in these animals. They found histopathologic findings comparable to human influenza virus pneumonia with intraalveolar edema and interstitial inflammatory cell infiltrates, and changes including alveolar epithelial hyperplasia at day seven.

Numerous studies have examined HPAI H5N1 viruses in experimental animal models, including mice and ferrets (100–104). Studies in both animals show a similar pathologic spectrum with bronchopneumonia, desquamation of bronchial and bronchiolar epithelial cells, diffuse alveolar interstitial inflammation, intraalveolar edema, and alveolar pneumocyte hyperplasia. Immunohistochemical analysis for the distribution of viral antigens shows positive staining in bronchial epithelial cells, alveolar pneumocytes, and alveolar macrophages. In both systems, viral encephalitis was also observed. Kuiken et al. (105) reported on the pathology of cynomolgus monkeys with a 1997 H5N1 virus. The histopathologic changes in the monkeys included extensive desquamation of bronchiolar and alveolar epithelium, interstitial inflammation and edema, intraalveolar edema, and hemorrhage admixed with numerous neutrophils and macrophages. One animal showed diffuse alveolar hyaline membrane formation. Upper airway changes were of a mild nature, but showed focal epithelial desquamation, ulceration, and inflammation.

With the completion of the project to sequence the 1918 influenza virus genome from autopsy tissues of 1918 influenza victims (57), it has become possible using reverse genetic techniques (106) to

NIH-PA Author Manuscript

Top

Abstract

INTRODUCTION

CONCLUSION

LITERATURE CITED

produce infectious viruses containing the 1918 influenza virus open reading frames (107–109) and to study experimental animal infections using mouse and cynomolgus monkey models. In both animals, the 1918 influenza virus replicated to high titers. In mice, infection with the 1918 virus produced a necrotizing bronchitis and bronchiolitis with a marked alveolitis, with infiltrates of neutrophils and macrophages. Alveolar edema was also observed. No evidence of systemic (nonrespiratory system) infection was noted. Gene expression array analysis demonstrated a marked activation of pre-inflammatory and cell death pathways one day after infection (108). In the monkeys, infection with the reconstructed 1918 influenza virus produced a fatal acute respiratory distress syndrome (109). Gene expression array analysis in this case demonstrated a dysregulation of the innate immune response and that the response was insufficient for protection.

CONCLUSION

Influenza viruses continue to be a major health threat in both endemic and pandemic forms. The rapid, continuous, and unpredictable nature of influenza viral evolution makes vaccine strategies and pandemic planning difficult. It is crucial that future pathology studies be performed on autopsies of victims with fatal influenza infections, whether caused by endemic strains, seasonal strains, or zoonotic strains such as the recent H5N1 viruses. Careful analysis of the histopathological changes of infection coupled with molecular genetic, virologic, and immunologic analyses will contribute to our understanding of the variable pathogenesis of influenza viruses.

SUMMARY POINTS

- Influenza viruses are common respiratory pathogens in humans.
- Influenza viruses can cause serious infections, leading to the development of pneumonia.
- Influenza A viruses, because of their host-range diversity, their genetic and antigenic diversity, and their ability to reassort genetically, are continual sources of novel influenza viruses that lead to the emergence of periodic pandemics.
- Pandemic influenza viruses cause much higher morbidity and mortality than annual, epidemic influenza virus outbreaks.
- Influenza virus infection includes both upper and lower respiratory tract involvement. Influenza virus pneumonia, either alone or with secondary bacterial pneumonias, can often be fatal.
- The worst influenza pandemic on record, the 1918 influenza, killed up to 50 million people globally.
- The pathologic spectrum of fatal influenza virus infections during the 1918 pandemic was not significantly different from that observed in other pandemics or even from fatal cases in seasonal influenza outbreaks.

NIH-PA Author Manuscript

NIH-PA Author Manuscript

NIH-PA Author Manuscript

NIH-PA Auth

Top

Abstract

INTRODUCTION

CONCLUSION

LITERATURE CITED

ACKNOWLEDGMENTS

This research was supported by the National Institute of Allergy and Infectious Diseases, a division of the Intramural Research Program of the National Institutes of Health.

DISCLOSURE STATEMENT

The authors are not aware of any biases that might be perceived as affecting the objectivity of this review.

LITERATURE CITED

1. Mulder J, Hers JFP. *Influenza.* Groningen: Wolters-Noordhoff; 1972. p. 287.
2. Wright PF, Neumann G, Kawaoka Y. Orthomyxoviruses. In: Knipe DM, Howley PM, editors. *Fields Virology.* 5th. Phladelphia: Lippincott Williams & Wilkins; 2007. pp. 1691–740.
3. Hirsch A. *Handbook of Geographical and Historical Pathology.* London: New Sydenham Soc.; 1883.
4. Thompson WW, Shay DK, Weintraub E, Brammer L, Cox N, et al. Mortality associated with influenza and respiratory syncytial virus in the United States. *JAMA.* 2003;289:179–86. [PubMed]
5. Cox NJ, Subbarao K. Global epidemiology of influenza: past and present. *Annu. Rev. Med.* 2000;51:407–21. [PubMed]
6. Taubenberger JK, Morens DM. 1918 influenza: the mother of all pandemics. *Emerg. Infect. Dis.* 2006;12:15–22. [PubMed]
7. Beveridge W. *Influenza: The Last Great Plague, an Unfinished Story.* New York: Prodist; 1977.
8. Simonsen L. The global impact of influenza on morbidity and mortality. *Vaccine.* 1999;17 (Suppl 1):S3–10. [PubMed]
9. Morens DM, Fauci AS. The 1918 influenza pandemic: insights for the 21st century. *J. Infect. Dis.* 2007;195:1018–28. [PubMed]
10. Johnson NP, Mueller J. Updating the accounts: global mortality of the 1918–1920 "Spanish" influenza pandemic. *Bull. Hist. Med.* 2002;76:105–15. [PubMed]
11. Finckh ES, Bader L. Pulmonary damage from Hong Kong influenza. *Aust. N.Z. J. Med.* 1974;4:16–22. [PubMed]
12. Guarner J, Paddock CD, Shieh WJ, Packard MM, Patel M, et al. Histopathologic and immunohistochemical features of

NIH-PA Author Manuscript NIH-PA Author Manuscript NIH-PA Author Manuscript

fatal influenza virus infection in children during the 2003–2004 season. *Clin. Infect. Dis.* 2006;43:132–40. [PubMed]

13. Guarner J, Shieh WJ, Dawson J, Subbarao K, Shaw M, et al. Immunohistochemical and in situ hybridization studies of influenza A virus infection in human lungs. *Am. J. Clin. Pathol.* 2000;114:227–33. [PubMed]

14. LeCount ER. The pathologic anatomy of influenzal bronchopneumonia. *JAMA.* 1919;72:650–52.

15. Leichtenstern O. Influenza. I. Geschichte, Epidemiologie und Aetiologie der Influenza. II. Pathologie und Therapie der Influenza. In: Nothnagel H, editor. *Nothnagel's Spezielle Pathologie und Therapie.* Vienna: Alfred Hölder; 1896. pp. 1–195.

16. Lindsay MI, Jr, Herrmann EC, Jr, Morrow GW, Jr, Brown AL., Jr Hong Kong influenza: clinical, microbiologic, and pathologic features in 127 cases. *JAMA.* 1970;214:1825–32. [PubMed]

17. Louria DB, Blumenfeld HL, Ellis JT, Kilbourne ED, Rogers DE. Studies on influenza in the pandemic of 1957–1958. II. Pulmonary complications of influenza. *J. Clin. Invest.* 1959;38:213–65. [PubMed]

18. Petersdorf RG, Fusco JJ, Harter DH, Albrink WS. Pulmonary infections complicating Asian influenza. *AMA Arch. Intern. Med.* 1959;103:262–72. [PubMed]

19. Travis WD, Colby TV, Koss MN, Rosado-de-Christenson ML, Muller NL, Talmadge EK., Jr. *Non-Neoplastic Disorders of the Lower Respiratory Tract.* Washington, DC: Am. Regist Pathol. Armed Forces Inst. Pathol.; 2002.

20. Winternitz MC, Wason IM, McNamara FP. *The Pathology of Influenza.* New Haven: Yale Univ. Press; 1920.

21. Wolbach SB. Comments on the pathology and bacteriology of fatal influenza cases, as observed at Camp Devens, Mass. *Johns Hopkins Hosp. Bull.* 1919;30:104–9.

22. Yeldandi AV, Colby TV. Pathologic features of lung biopsy specimens from influenza pneumonia cases. *Hum. Pathol.* 1994;25:47–53. [PubMed]

23. Peiris JS, Yu WC, Leung CW, Cheung CY, Ng WF, et al. Re-emergence of fatal human influenza A subtype H5N1 disease. *Lancet.* 2004;363:617–19. [PubMed]

24. Webby RJ, Webster RG. Are we ready for pandemic influenza? *Science.* 2003;302:1519–22. [PubMed]

NIH-PA Author Manuscript NIH-PA Author Manuscript NIH-PA Author Manuscript NIH-PA A

25. Webster RG, Govorkova EA. H5N1 influenza: continuing evolution and spread. *N. Engl. J. Med.* 2006;355:2174–77. [PubMed]

26. Taubenberger JK, Morens DM, Fauci AS. The next influenza pandemic: Can it be predicted? *JAMA.* 2007;297:2025–72. [PubMed]

27. To KF, Chan PK, Chan KF, Lee WK, Lam WY, et al. Pathology of fatal human infection associated with avian influenza A H5N1 virus. *J. Med. Virol.* 2001;63:242–46. [PubMed]

28. Uiprasertkul M, Puthavathana P, Sangsiriwut K, Pooruk P, Srisook K, et al. Influenza A H5N1 replication sites in humans. *Emerg. Infect. Dis.* 2005;11:1036–41. [PubMed]

29. de Jong MD, Simmons CP, Thanh TT, Hien VM, Smith GJ, et al. Fatal outcome of human influenza A (H5N1) is associated with high viral load and hypercytokinemia. *Nat. Med.* 2006;12:1203–7. [PubMed]

30. Peiris M. Pathogenesis of avian flu H5N1 and SARS. *Novartis Found Symp.* 2006;279:56–60. discussion 60–65, 216–19. [PubMed]

31. Cent. Dis. Control. Update: influenza activity: United States and worldwide, 1999–2000 season, and composition of the 2000–01 influenza vaccine. *MMWR Morb. Mortal. Wkly. Rep.* 2000;49:375–81. [PubMed]

32. Taubenberger JK, Layne SP. Diagnosis of influenza virus: coming to grips with the molecular era. *Mol. Diagn.* 2001;6:291–305. [PubMed]

33. Couch RB. Prevention and treatment of influenza. *N. Engl. J. Med.* 2000;343:1778–87. [PubMed]

34. Hay AJ, Gregory V, Douglas AR, Lin YP. The evolution of human influenza viruses. *Philos. Trans. R. Soc. Lond. B Biol. Sci.* 2001;356:1861–70. [PubMed]

35. Gensheimer KF, Meltzer MI, Postema AS, Strikas RA. Influenza pandemic preparedness. *Emerg. Infect. Dis.* 2003;9:1645–48. [PubMed]

36. World Health Org. Influenza in the world. 1 October 1999–30 September 2000. *Wkly. Epidemiol. Rec.* 2001;76:49–53. [PubMed]

37. Hayden FG. Update on influenza and rhinovirus infections. *Adv. Exp. Med. Biol.* 1999;458:55–67. [PubMed]

38. Monto AS, Robinson DP, Herlocher ML, Hinson JM, Jr, Elliott MJ, Crisp A. Zanamivir in the prevention of influenza among healthy adults: a randomized controlled trial. *JAMA.* 1999;282:31–35. [PubMed]

39. Hayden FG. Antiviral resistance in influenza viruses: implications for management and pandemic response. *N.*

Author Manuscript NIH-PA Author Manuscript NIH-PA Author Manuscript NIH-PA Author Manuscript

Engl. J. Med. 2006;354:785–88. [PubMed]

40. Hayden FG. Antivirals for influenza: historical perspectives and lessons learned. *Antiviral Res.* 2006;71:372–78. [PubMed]

41. Hayden FG, Pavia AT. Antiviral management of seasonal and pandemic influenza. *J. Infect. Dis.* 2006;194(Suppl 2):S119–26. [PubMed]

42. Monto AS, McKimm-Breschkin JL, Macken C, Hampson AW, Hay A, et al. Detection of influenza viruses resistant to neuraminidase inhibitors in global surveillance during the first 3 years of their use. *Antimicrob. Agents Chemother.* 2006;50:2395–402. [PubMed]

43. Palese P, Shah ML. Orthomyxoviridae: the viruses and their replication. In: Knipe DM, Howley PM, editors. *Fields Virology.* 5th. Philadelphia: Lippincott, Williams & Wilkins; 2007. pp. 1647–90.

44. Osterhaus AD, Rimmelzwaan GF, Martina BE, Bestebroer TM, Fouchier RA. Influenza B virus in seals. *Science.* 2000;288:1051–53. [PubMed]

45. Youzbashi E, Marschall M, Chaloupka I, Meier-Ewert H. [Distribution of influenza C virus infection in dogs and pigs in Bavaria]. *Tierarztl. Prax.* 1996;24:337–42. [PubMed]

46. Webster RG, Bean WJ, Gorman OT, Chambers TM, Kawaoka Y. Evolution and ecology of influenza A viruses. *Microbiol. Rev.* 1992;56:152–79. [PubMed]

47. Obenauer JC, Denson J, Mehta PK, Su X, Mukatira S, et al. Large-scale sequence analysis of avian influenza isolates. *Science.* 2006;311:1576–80. [PubMed]

48. Smith NM, Bresee JS, Shay DK, Uyeki TM, Cox NJ, Strikas RA. Prevention and control of influenza: recommendations of the Advisory Committee on Immunization Practices (ACIP). *MMWR Recomm. Rep.* 2006;55:1–42. [PubMed]

49. Chen R, Holmes EC. Avian influenza virus exhibits rapid evolutionary dynamics. *Mol. Biol. Evol.* 2006;23:2336–41. [PubMed]

50. Scholtissek C, Rohde W, Von Hoyningen V, Rott R. On the origin of the human influenza virus subtypes H2N2 and H3N2. *Virology.* 1978;87:13–20. [PubMed]

51. Kawaoka Y, Krauss S, Webster RG. Avian-to-human transmission of the PB1 gene of influenza A viruses in the 1957 and 1968 pandemics. *J. Virol.* 1989;63:4603–8. [PubMed]

52. Basler CF, Reid AH, Dybing JK, Janczewski TA, Fanning TG, et al. Sequence of the 1918 pandemic influenza virus nonstructural gene (NS) segment and characterization of recombinant viruses bearing the 1918 NS genes. *Proc. Natl. Acad. Sci. USA.* 2001;98:2746–51. [PubMed]

NIH-PA Author Manuscript

NIH-PA Author Manuscript

NIH-PA Author Manuscript

NIH-P

53. Reid AH, Fanning TG, Hultin JV, Taubenberger JK. Origin and evolution of the 1918 "Spanish" influenza virus hemagglutinin gene. *Proc. Natl. Acad. Sci. USA.* 1999;96:1651–56. [PubMed]

54. Reid AH, Fanning TG, Janczewski TA, Lourens RM, Taubenberger JK. Novel origin of the 1918 pandemic influenza virus nucleoprotein gene. *J. Virol.* 2004;78:12462–70. [PubMed]

55. Reid AH, Fanning TG, Janczewski TA, McCall S, Taubenberger JK. Characterization of the 1918 "Spanish" influenza virus matrix gene segment. *J. Virol.* 2002;76:10717–23. [PubMed]

56. Reid AH, Fanning TG, Janczewski TA, Taubenberger JK. Characterization of the 1918 "Spanish" influenza virus neuraminidase gene. *Proc. Natl. Acad. Sci. USA.* 2000;97:6785–90. [PubMed]

57. Taubenberger JK, Reid AH, Lourens RM, Wang R, Jin G, Fanning TG. Characterization of the 1918 influenza virus polymerase genes. *Nature.* 2005;437:889–93. [PubMed]

58. Reid AH, Taubenberger JK, Fanning TG. Evidence of an absence: the genetic origins of the 1918 pandemic influenza virus. *Nat. Rev. Microbiol.* 2004;2:909–14. [PubMed]

59. Rabadan R, Levine AJ, Robins H. Comparison of avian and human influenza A viruses reveals a mutational bias on the viral genomes. *J. Virol.* 2006;80:11887–91. [PubMed]

60. Gaydos JC, Top FH, Jr, Hodder RA, Russell PK. Swine influenza a outbreak, Fort Dix, New Jersey, 1976. *Emerg. Infect. Dis.* 2006;12:23–28. [PubMed]

61. Sencer DJ, Millar JD. Reflections on the 1976 swine flu vaccination program. *Emerg. Infect. Dis.* 2006;12:29–33. [PubMed]

62. Fouchier RA, Schneeberger PM, Rozendaal FW, Broekman JM, Kemink SA, et al. Avian influenza A virus (H7N7) associated with human conjunctivitis and a fatal case of acute respiratory distress syndrome. *Proc. Natl. Acad. Sci. USA.* 2004;101:1356–61. [PubMed]

63. Tweed SA, Skowronski DM, David ST, Larder A, Petric M, et al. Human illness from avian influenza H7N3, British Columbia. *Emerg. Infect. Dis.* 2004;10:2196–99. [PubMed]

64. World Health Org. *Cumulative Number of Confirmed Human Cases of Avian Influenza A/(H5N1) Reported to WHO.* Geneva: World Health Org.; 2007.

65. Ungchusak K, Auewarakul P, Dowell SF, Kitphati R, Auwanit W, et al. Probable person-to-person transmission of avian influenza A (H5N1). *N. Engl. J. Med.* 2005;352:333–40. [PubMed]

66. Jordan EO. *Epidemic Influenza: A Survey.*

A Author Manuscript NIH-PA Author Manuscript NIH-PA Author Manuscript NIH-PA Author Manuscri

Chicago: Am. Med. Assoc.; 1927.

67. Simonsen L, Clarke MJ, Schonberger LB, Arden NH, Cox NJ, Fukuda K. Pandemic versus epidemic influenza mortality: a pattern of changing age distribution. *J. Infect. Dis.* 1998;178:53–60. [PubMed]

68. Weichselbaum A. Beitrag zur Aetiologie und pathologischen Antatomie der Influenza. *Wiener klinische Wochenschr.* 1892;5:459–61.

69. Kuskow N. Zur pathologischen Anatomie der Grippe. *Virchow's Arch. Pathol. Anat.* 1895;139:406.

70. Askanazy M. Ueber die Veränderungen der grossen Luftwege, besonders ihre Epithel-Metaplasie bei der Influenza. *Corr. Bl. Schwiez Aerzte.* 1919;49:465.

71. Opie EL, Blake FG, Small JC, Rivers TM. *Epidemic Respiratory Disease: The Pneumonias and Other Infections of the Respiratory Tract Accompanying Influenza and Measles.* St. Louis: C.V. Mosby Co.; 1921.

72. MacCallum WG. Pathological anatomy of pneumonia associated with influenza. *Johns Hopkins Hosp. Rep.* 1921;20:149.

73. Lucke B, Wight T, Kime E. Pathologic anatomy and bacteriology of influenza. *Arch. Intern. Med.* 1919;24:154–237.

74. Opie EL. The pathologic anatomy of influenza. *Arch. Pathol. Lab. Med.* 1928;5:285–303.

75. Goodpasture EW. The significance of certain pulmonary lesions in relation to the etiology of influenza. *Am. J. Med. Sci.* 1919;158:863–70.

76. Klotz O. The pathology of epidemic influenza. In: Klotz O, editor. *Studies on Epidemic Influenza.* Pittsburgh: Univ. Pittsburgh Sch. Med.; 1919. pp. 207–93.

77. LeCount ER. Disseminated necrosis o the pulmonary capillaries in influenzal pneumonia. *J. Am. Med. Assoc.* 1919;72:1519–20.

78. Walker OJ. Pathology of influenza-pneumonia. *J. Lab. Clin. Med.* 1919;5:154.

79. Wolbach SB, Frothingham C. The influenza epidemic at Camp Devens in 1918. *Arch. Intern. Med.* 1923;32:571–600.

NIH-PA Author Manuscript NIH-PA Author Manuscript NIH-PA Author Manuscript

80. Smith W, Andrewes C, Laidlaw P. A virus obtained from influenza patients. *Lancet.* 1933;2:66–68. [PubMed]

81. Taubenberger JK, Hultin JV, Morens DM. Discovery and characterization of the 1918 pandemic influenza virus in historical context. *Antivir. Ther.* 2007;12:581–91. [PubMed]

82. Hers JF, Goslings WR, Masurel N, Mulder J. Death from Asiatic influenza in the Netherlands. *Lancet.* 1957;273:1164–65. [PubMed]

83. Hers JF, Masurel N, Mulder J. Bacteriology and histopathology of the respiratory tract and lungs in fatal Asian influenza. *Lancet.* 1958;2:1141–43. [PubMed]

84. Feldman PS, Cohan MA, Hierholzer WJ., Jr. Fatal Hong Kong influenza: a clinical, microbiological and pathological analysis of nine cases. *Yale J. Biol. Med.* 1972;45:49–63. [PubMed]

85. Noble RL, Lillington GA, Kempson RL. Fatal diffuse influenzal pneumonia: premortem diagnosis by lung biopsy. *Chest.* 1973;63:644–66. [PubMed]

86. Shope RE. Swine influenza. I. Experimental tranmission and pathology. *J. Exp. Med.* 1931;54:349–59.

87. Shope RE. Swine influenza. III. Filtration experiments and etiology. *J. Exp. Med.* 1931;54:373–85.

88. Shope RE. The infection of ferrets with swine influenza virus. *J. Exp. Med.* 1934;60:49–61.

89. Shope RE. The infection of mice with swine influenza virus. *J. Exp. Med.* 1935;62:561–72.

90. Andrewes CH, Laidlaw PP, Smith W. The susceptibility of mice to the viruses of human and swine influenza. *J. Exp. Med.* 1934;224:859–62.

91. Hers JF, Mudler J, Masurel N, van der Kuip L, Tyrrell DA. Studies on the pathogenesis of influenza virus pneumonia in mice. *J. Pathol. Bacteriol.* 1962;83:207–17. [PubMed]

92. Burnet FM. Influenza virus "A" infections of cynomolgus monkeys. *Aust. J. Exp. Biol.* 1941;19:281–90.

93. Clements ML, Snyder MH, Buckler-White AJ, Tierney EL, London WT, Murphy BR. Evaluation of avian-human reassortant influenza A/Washington/897/80× A/Pintail/119/79 virus in monkeys and adult volunteers. *J. Clin. Microbiol.* 1986;24:47–51. [PubMed]

94. Snyder MH, Clements ML, Herrington D, London WT, Tierney EL, Murphy BR. Comparison by studies in squirrel

NIH-PA Author Manuscript NIH-PA Author Manuscript NIH-PA Author Manuscript NIH-PA Author Manu

monkeys, chimpanzees, and adult humans of avian-human influenza A virus reassortants derived from different avian influenza virus donors. *J. Clin. Microbiol.* 1986;24:467–69. [PubMed]

95. Snyder MH, London WT, Maassab HF, Murphy BR. Attenuation and phenotypic stability of influenza B/Texas/1/84 cold-adapted reassortant virus: studies in hamsters and chimpanzees. *J. Infect. Dis.* 1989;160:604–10. [PubMed]

96. Snyder MH, London WT, Tierney EL, Maassab HF, Murphy BR. Restricted replication of a cold-adapted reassortant influenza A virus in the lower respiratory tract of chimpanzees. *J. Infect. Dis.* 1986;154:370–71. [PubMed]

97. Snyder MH, Stephenson EH, Young H, York CG, Tierney EL, et al. Infectivity and antigenicity of live avian-human influenza A reassortant virus: comparison of intranasal and aerosol routes in squirrel monkeys. *J. Infect. Dis.* 1986;154:709–11. [PubMed]

98. Baskin CR, Garcia-Sastre A, Tumpey TM, Bielefeldt-Ohmann H, Carter VS, et al. Integration of clinical data, pathology, and cDNA microarrays in influenza virus-infected pigtailed macaques (*Macaca nemestrina*). *J. Virol.* 2004;78:10420–32. [PubMed]

99. Baas T, Baskin CR, Diamond DL, Garcia-Sastre A, Bielefeldt-Ohmann H, et al. Integrated molecular signature of disease: analysis of influenza virus-infected macaques through functional genomics and proteomics. *J. Virol.* 2006;80:10813–28. [PubMed]

100. Maines TR, Chen LM, Matsuoka Y, Chen H, Rowe T, et al. Lack of transmission of H5N1 avian-human reassortant influenza viruses in a ferret model. *Proc. Natl. Acad. Sci. USA.* 2006;103:12121–26. [PubMed]

101. Maines TR, Lu XH, Erb SM, Edwards L, Guarner J, et al. Avian influenza (H5N1) viruses isolated from humans in Asia in 2004 exhibit increased virulence in mammals. *J. Virol.* 2005;79:11788–800. [PubMed]

102. Mase M, Tanimura N, Imada T, Okamatsu M, Tsukamoto K, Yamaguchi S. Recent H5N1 avian influenza A virus increases rapidly in virulence to mice after a single passage in mice. *J. Gen. Virol.* 2006;87:3655–59. [PubMed]

103. Nishimura H, Itamura S, Iwasaki T, Kurata T, Tashiro M. Characterization of human influenza A (H5N1) virus infection in mice: neuro-, pneumo- and adipotropic infection. *J. Gen. Virol.* 2000;81:2503–10. [PubMed]

104. Salomon R, Franks J, Govorkova EA, Ilyushina NA, Yen HL, et al. The polymerase complex genes contribute to the high virulence of the humanH5N1influenza virus isolate A/Vietnam/1203/04. *J. Exp. Med.* 2006;203:689–97. [PubMed]

105. Kuiken T, Rimmelzwaan GF, Van Amerongen G, Osterhaus AD. Pathology of human influenza A (H5N1) virus infection in cynomolgus macaques (*Macaca fascicularis*). *Vet.*

NIH-PA Author Manuscript

Pathol. 2003;40:304–10. [PubMed]

106. Fodor E, Devenish L, Engelhardt OG, Palese P, Brownlee GG, Garcia-Sastre A. Rescue of influenza A virus from recombinant DNA. *J. Virol.* 1999;73:9679–82. [PubMed]

107. Tumpey TM, Basler CF, Aguilar PV, Zeng H, Solorzano A, et al. Characterization of the reconstructed 1918 Spanish influenza pandemic virus. *Science.* 2005;310:77–80. [PubMed]

108. Kash JC, Tumpey TM, Proll SC, Carter V, Perwitasari O, et al. Genomic analysis of increased host immune and cell death responses induced by 1918 influenza virus. *Nature.* 2006;443:578–81. [PubMed]

109. Kobasa D, Jones SM, Shinya K, Kash JC, Copps J, et al. Aberrant innate immune response in lethal infection of macaques with the 1918 influenza virus. *Nature.* 2007;445:319–23. [PubMed]

Write to PMC | PMC Home | PubMed
NCBI | U.S. National Library of Medicine
NIH | Department of Health and Human Services
Privacy Policy | Disclaimer | Freedom of Information Act